

Successfully endoscopic retrieval of ingested toothpicks in colorectum : a report of four cases

L.N. Tan, Y.Y. Tan, D.L. Liu¹

Department of Gastroenterology, The Second Xiangya Hospital, Central South University, Changsha, Hunan 410011, China.

Abstract

Background : Toothpick ingestion is a rare event, but due to the low efficacy of radiographic examination, it can induce severe complications including perforation, abscess, and sepsis.

Case report : Four patients with either defecation problems or abdominal/anal pain were admitted to our hospital. Colonoscopy showed all four cases had a toothpick impacted in the colorectal wall without perforation. Direct retrieval of the toothpick under endoscopy was achieved. All four patients were relieved and remained well during the follow-up.

Conclusion : Endoscopy is the most effective method to discover or retrieve ingested wooden foreign bodies when there are no severe complications. (*Acta gastroenterol. belg.*, 2020, 83, 319-321).

Keywords : Colorectum, endoscopy, foreign body ingestion, toothpick.

Introduction

Foreign body ingestion is a common emergency. It is estimated that 1,500 people in the United States die from foreign body injuries in the upper gastrointestinal tract every year (1). Most impacted foreign bodies are located at the upper gastrointestinal tract (2) and patients often present with dysphagia, chest pain and odynophagia. Luckily, more than 80% foreign bodies will pass through the entire gastrointestinal tract uneventfully (3). Objects larger than 2 cm in diameter are less likely to pass the pylorus, and objects longer than 6 cm may be obstructed at the pylorus or duodenum (4). Therefore, long foreign bodies such as toothpicks in the colorectum are rare and difficult to diagnose without endoscopic examination. Herein we report four cases of toothpick ingestion in the colorectum (Table 1).

Case 1

A 45-year old male was admitted to our hospital due to four months of abnormal defecation with dry and effluvial stool and occasional melena. He had no abdominal pain or fever. He reported good physical health before presentation and no history of foreign body ingestion. Physical examination was unremarkable. The laboratory examination showed hemoglobin and leukocyte concentrations, and a neutrophil percentage of 12.5g/dL, $11.2 \times 10^9/l$, and 77.50%, respectively. Colonoscopy revealed a congestive mucosa in the sigmoid and rectal colon, and a prod embedded in the rectal wall located

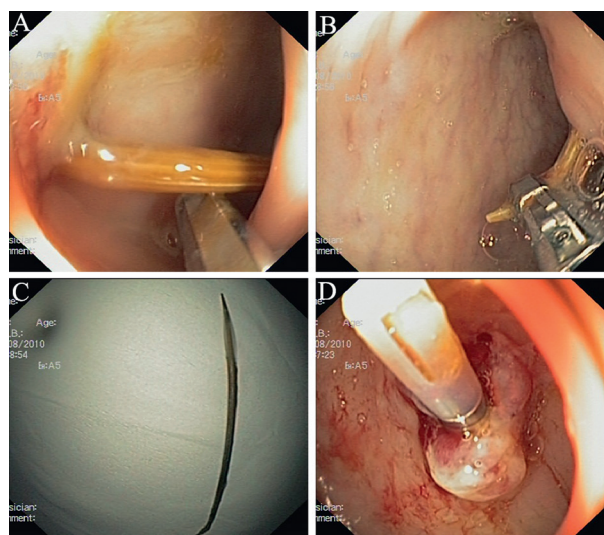


Figure 1. — Images of Case 1. A, Endoscopy showing the embedded toothpick in the rectum. B, Endoscopic removal of the toothpick. C, The removed toothpick. D, The embedded bowel wall was closed with clips after toothpick removal.

about 16 cm from the anal verge, surrounded by granulation tissue (Figure 1A). The foreign body did not penetrate into a large vessel or adjacent organs as shown in contrast-enhanced abdominal computed tomography (CT) with angiography, and no pneumatosis or abscesses were detected. The foreign body was successfully removed endoscopically and surgery was uneventful (Figure 1B). The foreign body was a 6 cm toothpick (Figure 1C). The wound was closed with a clip (Figure 1D). Antibiotics were administered for 2 days. Patient was relieved and remained well during a year of follow-up.

Correspondence to : De-Liang Liu, PhD, MD, director, Department of Gastroenterology, The Second Xiangya Hospital, Central South University, No. 139 Middle Renmin Road, Changsha, Hunan 410011, China.

E-mail : deliangliu@csu.edu.cn

Yu-Yong Tan, PhD, MD, Department of Gastroenterology, The Second Xiangya Hospital, Central South University, No. 139 Middle Renmin Road, Changsha, Hunan 410011, China.

E-mail : tanyuyong@csu.edu.cn

Submission date : 21/09/2019

Acceptance date : 29/12/2019

Table 1. — The baseline characteristics of four cases

Case	Age	Gender	Symptoms	Location of toothpick	Length of toothpick	Follow-up
Case 1	45	male	dry and effluvial stool and sometimes melena	rectum	6cm	1 year
Case 2	42	male	right upper quadrant abdominal pain, aggravated by position shift or eating	hepatic flexure of colon	6cm	1 year
Case 3	36	female	anal pain during defecation	rectum	2.5cm	6 months
Case 4	66	male	inferior abdominal pain	sigmoid colon	6cm	6 months

Case 2

A 42-year-old male presented to our department with right upper abdominal pain for 1 week. The pain worsened with change in body position or meal ingestion. Ultrasound at a local hospital suggested a rough gallbladder wall, and he was diagnosed with cholecystitis, but his symptoms were not alleviated after treatment with antibiotics. Physical examination revealed right upper abdominal tenderness. Laboratory results showed hemoglobin and leukocyte concentrations and a neutrophil percentage of 15 g/dL, $11.3 \times 10^9/l$, and 76.10%, respectively. Esophagogastroduodenoscopy was unremarkable. Colonoscopy showed a toothpick impaction in the hepatic flexure of the colon with both ends embedded in the colon wall and peripheral ulcers. He then recalled an accidental toothpick ingestion 3 weeks prior. Contrast-enhanced abdominal CT with angiography revealed no penetration of large vessels or adjacent organs, and no pneumatosis or abscesses. The toothpick was successfully removed endoscopically with foreign-body forceps; it was 6 cm long. No bleeding was detected, and intravenous antibiotics were administered for 2 days. His symptoms were relieved, and he remained well during 1 year of follow-up.

Case 3

A 36-year-old female visited our clinic due to painful defecation for 2 days. She reported good physical health before symptoms and no history of foreign body ingestion. She had no fever, diarrhea, or hematochezia. Physical examination showed tenderness at the left inferior abdomen. Laboratory examination showed hemoglobin, and leukocyte concentrations, and a neutrophil percentage of 12.8 g/dL, $6.5 \times 10^9/l$, and 75.6%, respectively. Endoscopy examination revealed a toothpick impaction in the rectal wall located near the anal verge. Contrast-enhanced abdominal CT with angiography did not find any penetration into a large vessel or adjacent organs, and no pneumatosis or abscesses. The toothpick was successfully removed endoscopically with foreign-body forceps and it was 2.5 cm long. There was no bleeding at the embedded site. Her pain was relieved, and she remained well during 6 months of follow-up.

Case 4

A 66-year-old male was hospitalized due to inferior abdominal pain for half a month. He reported a toothpick

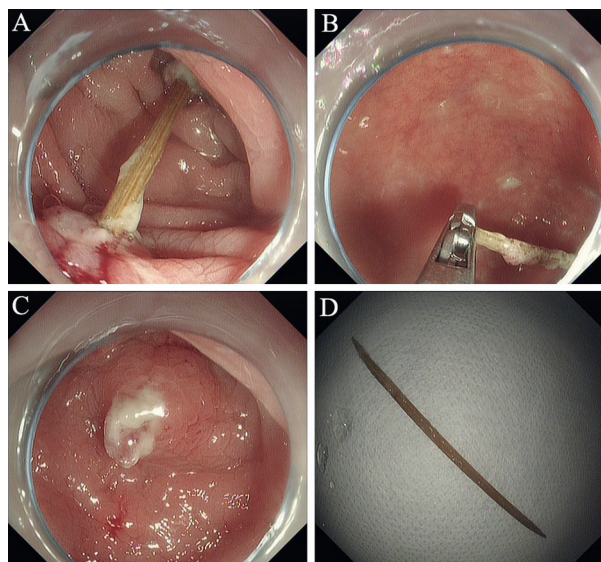


Figure 2. — Images of Case 4. A, Endoscopy showing the embedded toothpick in the sigmoid colon. B, Endoscopic removal of the toothpick. C, The embedded bowel wall after toothpick removal. D, The removed toothpick.

ingestion two months prior, when he had no symptoms. He had no fever, diarrhea, melena, or hematochezia. He denied any history of surgery or tumors. Physical examination showed tenderness at the left inferior abdomen. Laboratory examination showed hemoglobin and leukocyte concentrations, and a neutrophil percentage of 13.5 g/dL, $7.0 \times 10^9/l$, and 83.2%, respectively.

Endoscopy examination revealed a toothpick impaction in the sigmoid colon wall located 14 cm from the anal verge, surrounded by purulence (Figure 2A). Contrast-enhanced abdominal CT and angiography did not find any penetration into large vessels or adjacent organs, and no pneumatosis or abscesses were found. The toothpick was successfully removed endoscopically with foreign-body forceps (Figure 2B) with no bleeding (Figure 2C); it was 6 cm long (Figure 2D). His pain was relieved, and he remained well during 6 months of follow-up.

Discussion

The properties of the ingested foreign body determine the likelihood of spontaneous elimination or complications (5). A toothpick with bilateral sharp ends and rigid body can be embedded anywhere throughout

the gastrointestinal tract (6). Of the reported toothpick ingested cases, 79% are accompanied by perforation and a majority occur in the colon and rectum (5,7). A toothpick in the colorectum is difficult to diagnose for several reasons. First, the symptoms reported are usually nonspecific and can mimic colonic diverticulitis (8), pancreatic pseudotumor (9), among others. In the present four cases, the abnormal defecation in Case 1 is often presented in gastrointestinal tumors. Case 2 was initially diagnosed with cholecystitis. Pain during defecation in Case 3 is commonly seen in hemorrhoids or anal fissures. Case 4 was initially suspected of intestinal obstruction. Second, patients have difficulty recalling the ingestion of a toothpick. Chances are that some of them had alcoholic beverages while using toothpicks during mealtimes (10). A review reported that of 57 toothpick ingestion cases, only 12% of patients remembered swallowing a toothpick (2). In our series, only Case 2 and 4 reported a history of toothpick ingestion. Third, radiographic examination is limited in demonstrating the presence of a toothpick (1). Only 5.5-15% of wooden foreign bodies are detectable on standard plain film (11,12). The efficacy of ultrasonography to detect toothpicks is unclear (13). The discovery rate of CT is only 42.6% (7) and requires a special window width and level (14). Endoscopic examination is useful to locate the wooden foreign body.

Endoscopy is a safe and effective method for retrieval of an ingested foreign body in colorectum. Endoscopic removal is considered only with the exclusion of penetration into the large vessel or solid organs and any complications. There are several points that can be helpful. First, the toothpick should be clearly exposed by changing the patient's position. Second, a CO₂ insufflator is recommended during endoscopic removal. Third, direct removal can be performed when only one end of the toothpick is embedded ; when the two ends are embedded, remove the end closest to the vessels or organs first. If both ends are far from the vessels or organs, first remove the end with more severe inflammation or deeper ulcers. In our case series, as the toothpick was impacted in the wall of the colorectum and there was no penetration into the large vessels or adjacent organs or any pneumatosis and abscesses, we used grasping forceps with no need for laparotomy to remove them. All patients had no severe

complications, and their symptoms were relieved after endoscopic treatment.

In conclusion, our case series demonstrated that endoscopic treatment is safe and effective for select cases of ingested toothpicks in the colorectum.

Conflict-of-interest

The authors declare that they have no conflict of interests.

References

1. SUGAWA C., H. ONO, M. TALEB, C.E. LUCAS. Endoscopic management of foreign bodies in the upper gastrointestinal tract : A review. *World J. Gastrointest. Endosc.*, 2014, **6**(10) : 475-481.
2. LI S.F., K. ENDER. Toothpick injury mimicking renal colic : case report and systematic review. *J. Emerg. Med.*, 2002, **23**(1) : 35-38.
3. IKENBERRY S.O., T.L. JUE, M.A. ANDERSON, V. APPALANENI, S. BANERJEE, T. BEN-MENACHEM, *et al.* Management of ingested foreign bodies and food impactions. *Gastrointest. Endosc.*, 2011, **73**(6) : 1085-1091.
4. ABDULLAH B.J., L.K. TEONG, J. MAHADEVAN, A. Jalaludin. Dental prosthesis ingested and impacted in the esophagus and orolaryngopharynx. *J. Otolaryngol.*, 1998, **27**(4) : 190-194.
5. VELITCHKOV N.G., G.I. GRIGOROV, J.E. LOSANOFF, K.T. KJOSSEV. Ingested foreign bodies of the gastrointestinal tract : retrospective analysis of 542 cases. *World J. Surg.*, 1996, **20**(8) : 1001-1005.
6. DEPOORTER L., BILLIET, M. VERHAMME, W. VAN MOERKERCKE. A Toothpick a day, keeps the doctor away? *Acta Gastroenterol. Belg.*, 2019, **82**(1) : 97-98.
7. STEINBACH C., M. STOCKMANN, M. JARA, J. BEDNARSCH, J.F. LOCK. Accidentally ingested toothpicks causing severe gastrointestinal injury : a practical guideline for diagnosis and therapy based on 136 case reports. *World J. Surg.*, 2014, **38**(2) : 371-377.
8. JO M.H., H. NAMGUNG. Toothpick Colon Injury Mimicking Colonic Diverticulitis. *Ann. Coloproctol.*, 2018, **34**(3) : 157-159.
9. BARGIGGIA S., L. REDAELLI, C. VAILATI, F. TAGLIABUE, A. AIROLDI, F. PARENTE. Pancreatic pseudotumor caused by toothpick ingestion. *Gastrointest. Endosc.*, 2015, **82**(1) : 179-180.
10. LIM D.R., J.C. KUK, T. KIM, E.J. SHIN. Surgery for intra-abdominal abscess due to intestinal perforation caused by toothpick ingestion : Two case reports. *Medicine (Baltimore)*, 2019, **98**(36) : e17032.
11. ANDERSON M.A., W.L. NEWMAYER, 3RD, E.S. KILGORE, JR. Diagnosis and treatment of retained foreign bodies in the hand. *Am. J. Surg.*, 1982, **144**(1) : 63-67.
12. KOBBS J.K., A.R. HANSEN, B. KEEFE. A retained wooden foreign body in the foot detected by ultrasonography. A case report. *J. Bone Joint Surg. Am.*, 1992, **74**(2) : 296-298.
13. HORII K., O. YAMAZAKI, M. MATSUYAMA, I. HIGAKI, S. KAWAI, Y. SAKAUE. Successful treatment of a hepatic abscess that formed secondary to fish bone penetration by percutaneous transhepatic removal of the foreign body : report of a case. *Surg. Today*, 1999, **29**(9) : 922-926.
14. LEE S.B., R.K. LEE, J.H. SUH, J.W. CHOI, C.Y. HA, C. KANG. A Case of Wooden Foreign-Body Ingestion. *J. Emerg. Med.*, 2018, **54**(1) : 121-123.