

Giant peritoneal loose body : a case report and review of the literature

L. Baert¹, S. De Coninck¹, C. Baertsoen¹, P. Lissens², L. Djoa³

(1) Sint- Andries Ziekenhuis Tielt, Department of Gastroenterology ; (2) Sint- Andries Ziekenhuis Tielt, Department of Surgery ; (3) Sint- Andries Ziekenhuis Tielt, Department of Radiology.

Abstract

We present a case about a 53-year-old man who complained of abdominal pain and constipation. Computed tomography showed a well-described nodular structure of 6cm in size with a central dense core of 0.5cm with compression against the rectosigmoid. The presence of a foreign body was suggested and a diagnostic laparoscopy was performed. Surgery revealed a giant peritoneal loose body measuring 5.5cm in diameter. After the removal, the patient was relieved of his symptoms.

Peritoneal loose bodies are usually small and asymptomatic. They are mostly found incidentally during laparotomy. Giant peritoneal loose bodies are a rare entity and diagnosis is difficult. A review of the literature is presented. (*Acta gastroenterol. belg.*, 2019, 82, 441-443).

Key words : Giant peritoneal loose body, appendices epiploicae

Introduction

Peritoneal loose bodies are an uncommon finding and are mostly found incidentally. Giant peritoneal loose bodies (more than 5cm) are very rare and only a few cases have been described (1-2,4-15). The most common etiology is the chronic torsion of an appendix epiploica (3). Because of the rarity of this lesions, diagnosis is difficult. We report a case of a symptomatic giant peritoneal loose body and give an update about the existing literature.

Case report

A 53- year-old man with a history of a squamous cell carcinoma of the soft palate was treated with a complete surgical excision 3 years ago. He developed a recurrence in the right tonsil 1 year later, which was treated with radiotherapy, complicated by a radiation stomatitis, for which enteral nutrition with a PEG tube was necessary. This tube could be removed 6 months after placement. The patient presented to the emergency department 1 year later with complaints of abdominal pain, located in the lower abdomen. He also experienced problems of constipation with evacuation of hard stools. There was no rectal blood loss. There were episodes of intermittent vomiting, anorexia and pyrosis. His weight had remained unchanged. He did not experience any urinary symptoms. He started drinking alcohol again (8 units a day) and smoked 20 cigarettes a day.

Clinical examination at presentation showed a good general condition. He had no fever and vital signs were

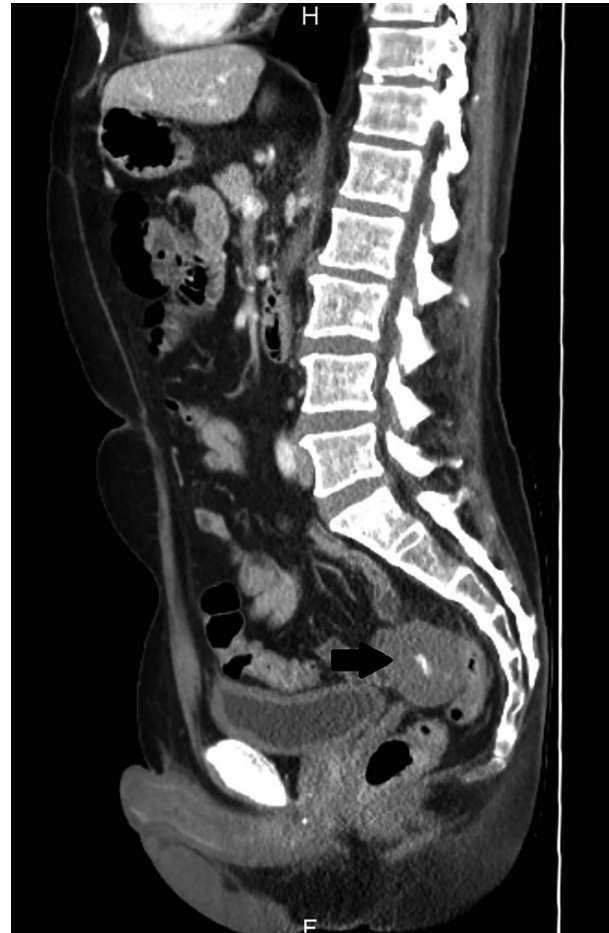

Figure 1. — Computed tomography scan showing a well-described nodular structure of 6 cm with a central dense core of 0.5cm, localized next to the rectosigmoid.

normal. Cardiopulmonary auscultation revealed no abnormalities. Clinical examination of the head and neck showed no enlarged lymph nodes and throat inspection was normal. Abdominal examination was painless and showed no enlarged organs or masses. Digital rectal examination showed the presence of multiple hard stools without any signs of blood.

Correspondence to : Lieselot Baert, UZ Gent, Department of Gastroenterology, De Pintelaan 185, 9000 Gent, Belgium.
E-mail : lieselot.baert@Ugent.be

Submission date : 24/01/2018
Acceptance date : 05/03/2018

Acta Gastro-Enterologica Belgica, Vol. LXXXII, July-September 2019

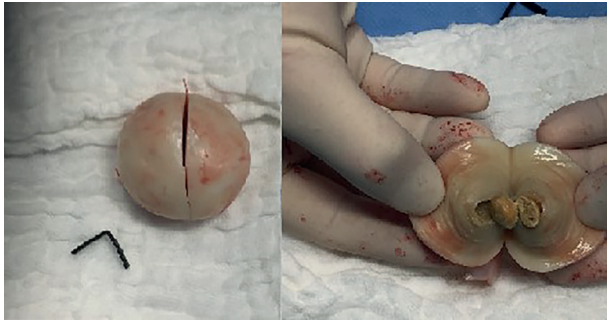


Figure 2. — A peritoneal loose body of 5.5cm with a yellow-white color and a calcified core. Pathological examination showed a central zone of fibrosis with calcifications, surrounded by lamellar structures.

Baseline blood investigations showed only slightly elevated liver function tests, due to the consumption of large amounts of alcohol. A chest X-ray was normal. A gastroscopy showed an esophageal ulcer and gastritis.

Additionally an ultrasound was performed with normal imaging of liver, spleen, pancreas and gallbladder. However, the radiologist described the presence of an oval structure with a central reflective core, presumably located in the rectum and suspect for a foreign object. An additional rectosigmoidoscopy confirmed the presence of hard stools, but there was no foreign body located. A CT scan was performed, confirming the presence of a well-described nodular structure with a central dense core, localized next to the rectosigmoid and with compression against it (Figure 1). The radiologist suggested the presence of a foreign body, possibly a rest of the previously placed PEG-tube. However, this seemed to be removed uneventfully one year before.

After a multidisciplinary consultation, a diagnostic laparoscopy was performed. During the operation, the surgeons found an oval, egg-shaped lesion adjacent to the rectosigmoid colon, which had the appearance of a boiled egg. The mass was 5.5cm big and had a yellow-white color (Figure 2). The lesion was free in the abdomen and could be removed through the right iliac fossa. Further exploration did not show any abnormalities. Pathological examination showed that the egg had a central zone with fibrosis and calcification, which was surrounded by lamellar structures, consisting of acellular fibrotic tissue. The diagnosis of a giant peritoneal loose body was made. Postoperatively, the patient left the hospital in a good condition and had no complaints of abdominal pain or constipation during follow-up.

Discussion

Peritoneal loose bodies are an uncommon finding. Especially the giant form with a diameter of more than 5 centimeter has rarely been described. They are mostly found in men and are mainly diagnosed between the age of 50 and 70 years old (1,2). There is limited information about the incidence and until now, only a few cases have

been described in the literature. The exact pathogenesis is unknown. The most frequently described etiology is the chronic torsion of an epiploic appendix (1,3). As a consequence of chronic torsion, the blood supply is shut off. This causes local ischemia with infarction and an aseptic fat necrosis. Afterwards, there appears a saponification and calcification of the fat tissue and the pedicle atrophies. Finally, there is a detachment and the appendix becomes a peritoneal loose body. The subsequent growth is explained by an accumulation of peritoneal serum around the loose body. Because of the increased temperature in the peritoneal cavity, this can cause the appearance of a boiled egg (1-8).

The largest peritoneal loose body that has been described was a mass measuring 10cm by 9.5cm by 7.5cm (5). Some case reports even described the simultaneously discovery of multiple giant peritoneal loose bodies (6). The growth speed is unknown but appears to be slow. One author described an increase in size of a peritoneal loose body from 7.5 x 7.0 cm to 9.5 x 7.5 cm after 5 years (7). Another case report described no significant change in size or appearance in 3 years time (8).

Other etiologies of peritoneal loose bodies that have been described are an auto-amputated adnexa (9), uterine leiomyoma (10), omentum or fat tissue in the pancreas (1). Recently, the first case of a loose body arising from a previous medically managed ectopic pregnancy was also described (11).

Peritoneal loose bodies are mobile, pelvic masses. They are mostly found to be free-floating in the pelvic cavity because of their tendency to gravitate to the most dependent part of the abdominal cavity (2,8). They are usually small ranging from 0.5 to 2cm in size. Due to their small size, they rarely cause symptoms and are mostly found accidentally. Occasionally, they can become larger than 5cm in diameter. At this size, they are called giant peritoneal loose bodies and can cause symptoms by compressing surrounding structures. The symptoms that have been described in the literature range from abdominal discomfort, pain and intermittent constipation (7) to small bowel obstruction (4,12,13), urinary retention, frequency and infections (14). Sometimes, the peritoneal loose body can attach to other organs and receive blood supply from it (a parasitized peritoneal body) (4,12).

Due to the rarity of this lesion, diagnosis is challenging. Differential diagnosis is broad and could range from benign disease like a leiomyoma or teratoma; to malignancy like colorectal, ovarian cancer, lymphoma of metastases. Other diagnoses that should be excluded are calculous disease, tubercular granulomas or foreign bodies (1,2,7,8,12).

On plain abdominal films, the appearance of a peritoneal loose body has been described as a calcified mass (2,8). On ultrasound, it can be seen as a hypoechoic round mass which could change position under probe compression (15). To differentiate from other lesions, a CT or MRI scan can be used. On a CT scan it shows a

concentric round or oval-shaped, well-defined mass with central calcification surrounded by peripheral soft tissue. MRI shows a low-intensity mass on both T1 and T2 weighted images, which makes it difficult to discriminate from a leiomyoma or teratoma. CT is useful in this discrimination because contrast enhancement is achieved in a leiomyoma or teratoma, while the appearance of peritoneal loose bodies remains unchanged (1,2,8,12,14). Another trick to differentiate them is the fact that they are freely mobile masses and follow-up imaging with varying the patient's body position can demonstrate a change of mass location (2,6,8).

Despite this, diagnosis is still difficult seen the rarity of the lesions and it is mostly made during an explorative laparoscopy, where they have a characteristic appearance of an eggshaped, white, hard glistening concretion. Pathological findings include a core of necrotic, calcified fat laminated by layers of acellular hyalinised fibrous tissue (8).

Considering the nature of peritoneal loose bodies, no treatment is required if they are asymptomatic. However, when there are symptoms or when there is a pelvic mass of unclear origin, laparoscopic exploration and removal may be required. Until now, no recurrences have been described.

References

- ZHANG H., LING Y.Z., CUI M.M., XIA Z.X., FENG Y., CHEN C.S. Giant peritoneal loose body in the pelvic cavity confirmed by laparoscopic exploration: a case report and review of the literature. *World J. Surg. Oncol.*, 2015, **13** : 118.
- KIM H.S., SUNG J.Y., PARK W.S., KIM Y.W. A giant peritoneal loose body. *Korean J. Pathol.*, 2013, **47** : 378-82.
- DESAI H.P., TRIPODI J., GOLD B.M., BURAKOFF R. Infarction of an epiploic appendage. Review of the literature. *J. Clin. Gastroenterol.*, 1993, **16** : 323-5.
- SEWKANIA., JAIN A., MAUDAR K.K., VARSHNEY S. 'Boiled egg' in the peritoneal cavity – a giant peritoneal loose body in a 64-year-old man: a case report. *J. Med. Case Rep.*, 2011, **7** : 297.
- SUSSMAN R., MURDOCK J. Images in clinical medicine. Peritoneal loose body. *N. Engl. J. Med.*, 2015, **372** : 1359.
- TAKADA A., MORIYA Y., MURAMATSU Y., SAGAE T. A case of giant peritoneal loose bodies mimicking calcified leiomyoma originating from the rectum. *Jpn. J. Clin. Oncol.*, 1998, **28** : 441-2.
- MOHRI T., KATO T., SUZUKI H. A giant peritoneal loose body: report of a case. *Am. Surg.*, 2007, **73** : 895-6.
- GAYER G., PETROVITCH I. CT diagnosis of a large peritoneal loose body: a casereport and review of the literature. *Br. J. Radiol.*, 2011, **84** : e83-5.
- KOGA K., HIROI H., OSUGA Y., NAGAI M., YANO T., TAKETANI Y. Autoamputated adnexa presents as a peritoneal loose body. *Fertil. Steril.*, 2010, **93** : 967-8.
- SUGANUMA I., MORI T., TAKAHARA T., TORII H., FUJISHIRO M., KIHIRA T. et al. Autoamputation of a pedunculated, subserosal uterine leiomyoma presenting as a giant peritoneal loose body. *Arch. Gynecol. Obstet.*, 2015, **291** : 951-953.
- COOKE W.R., KIRK E. Medically managed tubal ectopic pregnancy presenting as a peritoneal loose body. *B.M.J. Case Rep.*, 2015 Sep 3: doi : 10.1136/bcr-2015-211871.
- TAKABE K., GREENBERG J.I., BLAIR S.L. Giant peritoneal loose bodies. *J. Gastrointest. Surg.*, 2006, **10** : 465-8.
- GHOSH P., STRONG C., NAUGLER W., HAGHIGHI P., CARETHERS J.M. Peritoneal mice implicated in intestinal obstruction: report of a case and review of the literature. *J. Clin. Gastroenterol.*, 2006, **40** : 427-30.
- MAKINENI H., THEJESWI P., PRAHBU S., BHAT R.R. Giant peritoneal loose body: a case report and review of the literature. *J. Clin. Diagn. Res.*, 2014, **8** : 187-8.
- OOYAGI H., ISHIDA H., KOMATSUDA T., YAGISAWA H. Peritoneal loose body. *J. Med. Ultrason.*, 2006, **33** : 189-90.