

## Efficacy of endoscopic ultrasound fine needle aspiration in diagnosing the rare (non-adenocarcinoma) tumors of pancreas

Mahmud Baghbanian<sup>1</sup>, Ali Baghbanian<sup>2</sup>, Hasan Salmanroghani<sup>1</sup>, Mohammad Ghezlou<sup>3</sup>, Mohsen Bakhtpour<sup>4</sup>, Bijan Shabazkhani<sup>5</sup>

(1) Department of gastroenterology, Shaheed Sadoughi University of medical sciences, Yazd, Iran ; (2) Department of psychiatry, Iran University of medical sciences, Tehran, Iran ; (3) Department of gastroenterology, Arak University of medical sciences, Arak, Iran ; (4) Department of nursing, Isfahan University of medical sciences, Isfahan, Iran ; (5) Department of gastroenterology, Tehran University of medical sciences, Tehran, Iran.

### Abstract

**Background :** Five percent of pancreatic neoplasms are non-adenocarcinoma tumors. Clinical presentation and imaging characteristics of these tumors are similar to adenocarcinoma. This study aims at evaluating the results and efficacy of Endoscopic ultrasound guided fine needle aspiration (EUS-FNA) in diagnosing the pancreatic non-adenocarcinoma tumor in patients with solid pancreatic mass.

**Methodology :** The present study which is of a descriptive, prospective and case series nature, has been studying the diagnostic value of EUS-FNA in pancreatic non-adenocarcinoma tumor in 60 patients with pancreatic solid neoplasm. Cytopathologic diagnosis founded on EUS-FNA accepted as final diagnosis in unresectable ones. But the reference standard for the final diagnosis in patients with resectable tumor was surgical pathology. In patients with non diagnostic EUS-FNA specimen, final diagnosis achieved by re-FNA, Computerized Tomography (CT) guided biopsy, or surgery.

**Results :** Ten patients (17%) found to have non-adenocarcinoma tumor. Half of them were male. EUS-FNA was diagnostic in 8 cases (80%) including the 4 neuroendocrine tumors, one gastrointestinal stromal tumor, one mucinous neoplasm, one pseudopapillary tumor, and one geant cell tumor. Surgical pathology confirmed the EUS-FNA diagnosis in five patients that had resectable tumor. However EUS-FNA recognition accepted as final diagnosis in three patients that had unresectable tumor. EUS-FNA was non-diagnostic in one patient with pancreatic lymphoma and another patient with colon cancer metastasis.

**Conclusion :** EUS FNA is a safe and effective for diagnosing the solid non- adenocarcinoma tumors as well as adenocarcinomas of pancreas. (*Acta gastroenterol. belg.*, 2014, 77, 312-317).

**Key words:** endoscopic ultrasound-guided fine-needle aspiration biopsy, pancreas, endocrine tumor, gastrointestinal stromal tumor, mucinous neoplasm, pseudopapillary tumor, geant cell tumor.

### Introduction

More than 95% of the pancreatic malignant neoplasms are adenocarcinomas which arise from the exocrine elements of the pancreas. Majority of these epithelial tumors are ductal adenocarcinoma and only 1% to 2% of them are acinar cell carcinoma. Non-adenocarcinoma neoplasms such as pancreatic endocrine tumor (PET), Solid pseudopapillary neoplasm (SPN), and sarcoma account for only about 5% of pancreatic neoplasms.

In patients who have resectable pancreatic cancer (according to the imaging) preoperative confirmation of malignancy is not always necessary. However, EUS-guided fine-needle aspiration is the procedure of choice in the presence of any doubt, and also for use in patients

who need neoadjuvant treatment. EUS-FNA is an effective and safe procedure for histopathologic assessment of the pancreatic solid tumors including malignant or non-malignant, and resectable or non-resectable ones (1,2). EUS-FNA with 85% to 90% accuracy (1,3) has a smaller risk of intraperitoneal dissemination compared with the percutaneous route.

Non-adenocarcinoma malignancies such as PET, SPN, lymphoma, mucinous neoplasm, giant cell tumor, and gastrointestinal stromal tumor (GIST) arise from non-epithelial components of pancreas. They are exceedingly rare (4) and carry a better prognosis rather than/ compared to adenocarcinoma ones (5). Identification of these rare pancreatic tumors is important both for patient prognosis, and appropriate therapeutic approach. But because of similar clinical presentation and imaging characteristics, preoperative differentiation of pancreatic non-adenocarcinoma tumors from adenocarcinoma had been difficult before the emergence of EUS-guided FNA biopsy. With the invention of EUS-FNA as a safe and reliable diagnostic procedure in the past 2 decades, this problem has been solved greatly (6).

This two-center study aims at evaluating the results and efficacy of EUS-FNA in diagnosing the pancreatic non-adenocarcinoma tumors among 120 patients with pancreatic solid mass.

### Patients and methods

The present study which is of a descriptive, prospective and case series nature, has evaluated consecutive patients with pancreatic solid mass, referred to two educational centers including Imam Khomeini hospital in Tehran and Shaheed Sadoughi hospital in Yazd from 2010 to 2013. Cystic or solid cystic-masses were not included.

Correspondence to : Mahmud Baghbanian, Endoscopy ward, Shaheed Sadoughi hospital, Ebnesina square, Yazd, Iran. E-mail : baghbanian1352@gmail.com

Submission date : 15/12/2013

Acceptance date : 08/05/2014

EUS-FNA procedures were carried out by two gastroenterologists. All patients were placed under conscious sedation using oropharyngeal topical anesthetic and intravenous midazolam and fentanyl with or without propofol. The echo endoscope used was curved linear array (Olympus GF-UC 24OP-AL5 Tokyo, Japan.) with Aloka Prosound SSD-5000 (Aloka, Tokyo, Japan) processor. EUS-guided FNA was carried out using a single use aspiration 22-G 13-mm Wilson-Cook Quick needle (Wilson-Cook GI Endoscopy, Winston-Salem, NC, USA). Approximately  $7 \pm 2$  back-and-forth passages were performed while maintaining aspiration in the needle.

One slide was air-dried and examined immediately with a rapid staining method (Diff-Quick stain ; International Reagents, Kobe, Japan) to verify adequacy of the specimen and give a presumptive diagnosis, if possible. Material was also preserved in 10% formalin and processed as a tissue block for histopathologic evaluation with hematoxylin-eosin and immunohistochemical (IHC) stains.

Reference standard for the final diagnosis was surgical pathology in patients with resectable tumors. However cytopathologic diagnosis found on EUS-FNA was accepted as final diagnosis in unresectable ones. In patients with non diagnostic EUS - FNA specimen, final diagnosis achieved via re-FNA, CT guided biopsy, and/or exploratory laparotomy.

### Statistical analysis

The significance level was 5% for all statistical procedures. Numerical variables were expressed as mean  $\pm$  SD. Concerning the diagnosis obtained by EUS-FNA, sensitivity, specificity, positive and negative predictive values, and accuracy were calculated with a  $2 \times 2$  table.

### Results

One hundred twenty patients with solid pancreatic mass participated in the present study. Majority of the patients (67%) were male. The mean age was 66 years (range 24-92) ; the 24-year-old patient was a woman with lymphoma and the 92-year-old patient was a man who found to have adenocarcinoma. The lesion was situated in the head of pancreas in 96 cases (80%). The mean lesion size was 44 millimeters (mm) ; the biggest mass was a gastrointestinal stromal tumor with 105 mm in diameter and the smallest lesion was lymphoma with 25 mm diameter.

EUS-FNA and cytological examination was performed in all 120 patients without any complication. The final diagnosis obtained in 113 patients : by first EUS-FNA in 101 cases, by second EUS-FNA in 4 cases, by surgical specimen in 4 cases, by CT scan guided biopsy in two cases, and by peritoneal fluid cytology in two cases. Result of histopathologic evaluation was adeno-

carcinoma in 97 cases (81%), non adenocarcinoma tumor in 11 ones (9%), benign lesion in 4 cases (3%) and non-diagnostic in 8 patient (7%). First EUS-FNA was diagnostic in 84% (101/120) of our cases.

The patients with rare neoplasms included 5 males and 6 females. Mean age of them was 53 years (range, 20-76years). The characteristics of these non-adenocarcinoma tumors are given in Table 1.

EUS-FNA was diagnostic in 81% (9/11) of patients with non-adenocarcinoma tumor including 4 PETs, one GIST, one mucinous neoplasm, 2 SPNs, and one geant cell tumor.

EUS-FNA was not diagnostic in two patients with non-adenocarcinoma tumor including a 24-year-old woman with pancreatic lymphoma and a 67-year-old man with metastatic colon cancer ; these lesions were diagnosed finally via supra clavicular lymph node excision and CT guided core biopsy of pancreatic mass respectively.

According to the clinical presentation and pre-EUS-FNA imaging such as multi detector computerized tomography scan (MDCT), magnetic resonance imaging (MRI), there wasn't any suspicion for non-adenocarcinoma tumor except in patient who had lymphoma.

Based on pancreatic protocol contrast multi detector computerized tomography scan and EUS, tumor was resectable in 6 patients with rare tumors including two neuroendocrine neoplasm cases, one case with mucinous neoplasm, 2 patients with solid pseudopapillary neoplasm, and one patient with osteoclast-like geant cell tumor. These 6 patients that underwent partial pancreatectomy ; histopathologic assessment and immunohistochemical staining of surgical specimens confirmed the preoperative diagnosis found on EUS-FNA in all of these 6 cases. However remained 5 patients including 2 cases with endocrine neoplasm, one case with gastrointestinal stromal tumor, one patient with lymphoma, and one case with colon cancer metastasis weren't found to have resectable tumors and didn't schedule for resection.

Despite prescription of Imatinib for patient with GIST, he died due to severe upper gastrointestinal bleeding four months later. Two other male patients, i.e., a 76-year-old with unresectable endocrine tumor and a 67-year-old with colon cancer metastasis died due to progression of malignancy. In those cases undergoing surgery, the disease didn't relapse in four of them in the following 2.5 years. Such cases included two patients with PET, one case with mucinous neoplasm, and two cases with SPN. However the 51-year-old woman with osteoclast like geant cell tumor, experienced tumor relapse as lymphadenopathy and liver metastasis seven months after surgery ; this patient and two other patients including the 24-year-old woman with lymphoma and 54-year-old woman with PET were on chemotherapy after 2.5 years.

After 2.5 years follow up, 5 cases (45%) were tumor free, 3 patients (30%) died due to progression of malignancy, and 3 cases (30%) had residual malignancy and were on chemotherapy.

Table 1. — Age, gender, tissue sampling method, final diagnosis, treatment, and outcome of patients with pancreatic non-adenocarcinoma tumor in our study

Number	Final diagnosis	Tumor size (millimeter)	Age (year)	Gender	Sampling method	Therapy method	Outcome (2 years follow up)
1	Endocrine tumor	100	67	Male	EUS-FNA*	Chemo®	Death
2	Endocrine tumor	45	46	Male	EUS-FNA	Surgery	Cure
3	Endocrine tumor	48	50	Male	EUS-FNA	Surgery	Cure
4	Endocrine tumor	50	54	Female	EUS-FNA	Chemo®	Residual disease
5	GIST †	105	57	Male	EUS-FNA	Imatinib	Death
6	Mucinous neoplasm	40	61	Female	EUS-FNA	Surgery	Cure
7	SPN ‡	29	45	Female	EUS-FNA	Surgery	Cure
8	SPN	35	52	Female	EUS-FNA	Surgery	Cure
9	Osteoclast-like giant cell tumor	70	51	Female	EUS-FNA	Surgery/Chemo®	Residual disease
10	Lymphoma‡	25	24	Female	Lymph node excision	Chemo®	Residual disease
11	Colon cancer metastasis ‡	30	76	Male	CT guided biopsy	Chemo®	Death

\*Endoscopic ultrasound guided fine needle aspiration, †Gastrointestinal stromal tumor, Chemo® Chemotherapy, ‡ Solid pseudopapillary neoplasm, ‡ EUS-FNA was non-diagnostic.

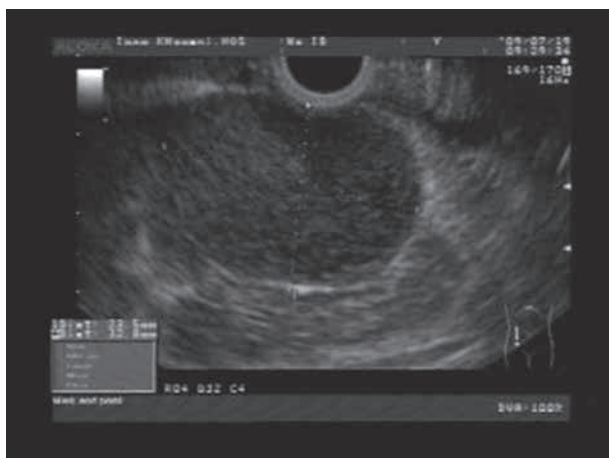


Fig. 1. — EUS shows 3 centimeter tumor with mixed echo in the head of the pancreas.

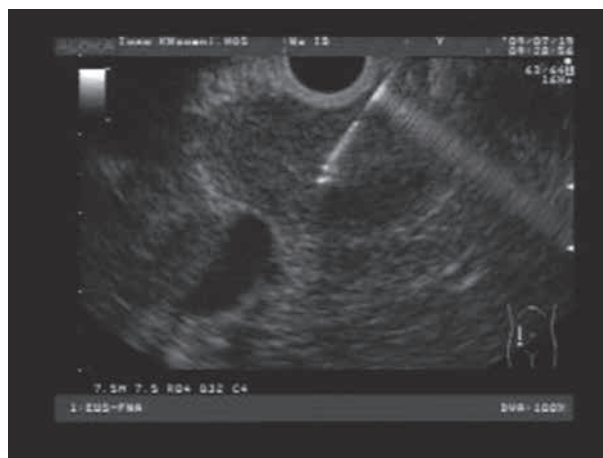

Fig. 2. — EUS shows 3 centimeter tumor with mixed echo in the head of the pancreas. You can see aspiration needle inside the mass (FNA).

## Discussion

In addition to adenocarcinoma that is the most common pancreatic tumor, there are various benign diseases and non adenocarcinoma neoplasms that manifest as pancreatic mass in clinic presentation and imaging characteristics. These lesions carry different prognosis and need different treatments ; in advanced adenocarcinoma and benign lesions such as autoimmune pancreatitis and few malignancies such as lymphoma, surgery is not needed. Moreover in masses where surgery is necessary, extent of surgical resection is different according to the tumor pathology. Due to inability of imaging in diagnosing of the tumor type, histopathologic diagnosis is essential for deciding about appropriate treatment in patients with pancreatic masses.

Fine needle aspiration (FNA) or biopsy can be performed through CT or ultrasound but both of these methods carry some difficulty and risks including seeding of the tumoral cells and damaging the adjacent tissues especially vessels. EUS-FNA that can reveal detailed characteristics of the tumor and provide an efficient and safe tissue sampling method doesn't carry these limitations (1).

Current main indications for EUS-FNA of pancreatic tumors are diagnosing unresectable ductal adenocarcinoma before chemotherapy and characterizing a pancreatic mass with atypical imaging features. However suspected or unsuspected pancreatic non adenocarcinoma tumors can be uncovered by this procedure. In this two-center experience we found 11 patients with non adenocarcinoma tumors among 120 patients with solid

Table 2. — Final diagnosis of the 5 patients in whom the first EUS-FNA was non contributive

	SEX	AGE (year)	TUMOR SIZE (millimeter)	TUMOR LOCATION IN PANCREAS	DIAGNOSING METHOD	FINAL DIAGNOSIS
PATIENT 1	Female	24	25	Head	surgical biopsy of supraclavicular lymph node	lymphoma
PATIENT 2	Male	76	30	Head	Computerized tomography guided biopsy	Metastasis of colon cancer
PATIENT 3	Male	54	40	Head	Repeated EUS-FNA	Pancreatic adenocarcinoma
PATIENT 4	Female	62	34	Head	Repeated EUS-FNA	Pancreatic adenocarcinoma
PATIENT 5	Male	58	30	Head	Repeated EUS-FNA	Died undiagnosed

pancreatic mass referred for EUS-FNA. EUS-FNA was diagnostic in 81% of rare tumors and 88% adenocarcinoma.

According to the Hiroshi Imaoka et al study, histopathologic assessment with immunohistochemical staining of material retrieved from EUS-FNA can correctly diagnose 67.9% of all rare pancreatic neoplasms ; despite high accuracy (85%) of EUS-FNA in diagnosing the solid non-adenocarcinoma tumors of the pancreas, diagnostic accuracy of this method in cystic non-adenocarcinoma neoplasms is only 25% (7). We didn't enroll the cystic lesion in our study.

Nine percent of our patients had non-adenocarcinoma tumor that is mildly more than other published data that reported 5%-10% prevalence of these tumors ; our patients are assessed consecutively in this study and we think this relatively high percentage of rare pancreatic tumor is true in our country.

According to the 5%-10% prevalence of non-adenocarcinoma tumor among the pancreatic neoplasms, we can accept that one case of the 8 non-diagnosed tumors in this study was been a non-adenocarcinoma type. So sensitivity, specificity, positive predictive value (PPV), negative predictive value (NPV), and accuracy of EUS-FNA for the differentiation of rare non-adenocarcinoma tumors from other solid pancreatic mass in the studied patients were 75% (9/12), 100% (108/108), 100% (9/9), 97% (109/112), and 93% (112/120) respectively.

Four PETs were found by EUS-FNA among 120 pancreatic solid masses (3%). Endocrine tumors account for 1% to 10% of tumors arising in the pancreas (8,9,10). PETs were diagnosed by EUS-FNA in five of 200 focal pancreatic lesions by Fritscher-Ravens *et al.* (11) and in 15 of 99 lesions by Voss *et al.* (12).

In our series, EUS-FNA was diagnostic in all of 4 endocrine tumors. Voss *et al.* (12) reported a lower accuracy (47%) of EUS-FNA for 15 PETs than for adenocarcinomas (81%). However, Gines *et al.* (13) reported 90% accuracy of EUS-FNA in ten patients.

Tissue sampling and diagnosis of PETs by FNA is difficult because these tumors are small in size, and are hypervascular (12).

But in the present study four endocrine tumors diagnosed by EUS-FNA were as large as 45 to 100 millimeters in diameter. The reason for the correct diagnosis is perhaps the large size of them.

Perhaps the greatest impact of EUS-FNA is diagnosing the pancreatic neuroendocrine tumors, and thus avoids an extensive resection for presumptive adenocarcinoma.

There was one *pancreatic metastasis* (0.8%) in our series. This lesion couldn't be characterized by EUS-FNA probably due to its relatively small size (30 mm). In this patient that was known case of colon cancer with liver metastasis, final diagnosis obtained by computerized tomography guided biopsy.

Metastasis to the pancreas manifest as pancreatic mass and can be diagnosed by EUS-FNA (14,15). Pancreatic metastasis previously considered rare may be more common than has been appreciated (16,17,18,19,20). Fritscher-Ravens *et al.* (21) reported that metastatic lesions comprised 11% of pancreatic masses referred for EUS-FNA. There is a wide range of latency between manifestation of the primary tumor and discovery of the metastasis. Thus, pancreatic metastases are often confused with primary pancreatic tumors. However diagnosis is imperative as long-term survival has been reported after surgical resection, and chemotherapy (22,23).

*Pancreatic SPN* that was seen in two cases (1.7%) of our patients was discovered by cytopathologic assessment and IHC staining of material retrieved from EUS-FNA in two women with solid pancreatic mass. They underwent uneventful tumor resection and the histopathologic diagnosis of surgical specimens was the same as EUS-FNA diagnosis. They were tumor free after two years.

SPN accounts for 1%-2% of all pancreatic neoplasms. These tumors occur predominantly in young women and are often asymptomatic. Utility of EUS-FNA for diagnosing solid pseudopapillary tumors has been described (24,25,26,27).

This tumor presents as well, demarcated, echo-poor, solid or mixed solid/cystic pancreatic lesion in EUS. As in our case, the cytological features and immuno-

histochemical staining of pancreatic SPN retrieved from EUS-FNA are distinctive (28). Over 95% of patients can be cured by complete surgical resection when the tumor is limited to the pancreas (29).

While local excision may suffice for localized tumors, long-term survival has been reported after aggressive surgical resection of metastatic disease, and even after debulking surgery (30). Consequently, the results of EUS-FNA can encourage surgical resection when a diagnosis of SPN is made.

*Pancreatic lymphoma* was seen in only one case (0.8%) of our patients; in this case EUS-FNA was not diagnostic and final diagnosis obtained via supra-clavicular lymph node excision. Unsuccessfulness of EUS-FNA in this patient might have been due to relatively small size of the tumor (25 mm) and special structure of lymphoma that is difficult for tissue sampling by FNA. Pancreas lymphoma manifests as pancreatic mass and can be diagnosed by EUS-FNA (14,15). It represents less than 1% to 2% of all pancreatic malignancies, and less than 1% of all extranodal non-Hodgkin's lymphomas (31). Whenever a large mass is identified in the pancreas without biliary obstruction, pain, or weight loss, the diagnosis should be contemplated. An elevated serum lactate dehydrogenase level supports a diagnosis of lymphoma. FNA biopsy with flowcytometry is highly accurate in establishing the diagnosis (32). Identification of pancreatic lymphoma is important because treatment is primarily nonsurgical, and prognosis is much better for pancreatic adenocarcinoma. Treatment usually consists of a combination of chemotherapy and radiation therapy, and cure rates near 30% are reported in the literature (32). A few patients with small tumors, thought to represent carcinomas, have been treated with surgery alone and have had excellent survival (31).

*Gastrointestinal Stromal Tumor of the pancreas* was proved according to the MDCT scan, EUS-FNA, histopathology, and immunohistochemical staining in one (0.8%) of our patients. This patient was a 57-year-old man with abdominal pain and palpable abdominal mass that was found to have a 105 mm solid mass in the head of the pancreas. Tumor was unresectable and Imatinib was prescribed for him but he died 4 months later due to severe gastrointestinal bleeding.

GISTs are mesenchymal tumors; most of them arise in the stomach, but may originate from other parts of the gastrointestinal tract. GIST can rarely occur in extraintestinal sites such as omentum, mesentery, or retroperitoneum. Pancreatic GIST is an extremely rare tumor with a few case reports in the literature. It can manifest as pancreatic solid mass with abdominal pain such as our case. Surgical resection with or without Imatinib is appropriate treatment in resectable ones.

*Mucinous cystic neoplasms (MCNs)* are the most frequently encountered cystic tumors of the pancreas, accounting for 10% to 45% of tumors. As in our single mucinous neoplasm case, cystic component of the tumor may disappear after malignant transformation. Histo-

pathologic diagnosis of our patient found in EUS-FNA was proved after distal pancreatectomy that was performed as curative treatment. As in our patient, MCNs occur almost exclusively in women, and are confined to body and/or tail of the pancreas. Mean age at presentation is 50 years. Most patients complain of abdominal pain or a palpable mass.

Diagnosis of *Pancreatic giant cell tumor* is described by EUS-FNA (7). Also in our study EUS-FNA revealed a 70 mm giant cell tumor in head of the pancreas in a 51-year-old woman with abdominal pain and palpable mass. This patient underwent curative pancreaticoduodenectomy; histopathologic assessment of the surgical specimen proved the preoperative diagnosis.

There are various pathologies with different prognosis presenting as pancreatic solid mass that need specific medical and or surgical treatment. Therefore diagnosing the tumor type is necessary for selecting the appropriate therapeutic strategy. EUS-FNA has high accuracy and safety in this field.

## Conclusion

Identifying the pancreatic tumor type is important key for selecting the appropriate therapeutic strategy. EUS-FNA is a safe and effective procedure for diagnosing the solid non-adenocarcinoma tumors as well as adenocarcinomas of the pancreas.

## Acknowledgements

The authors extend their gratitude to Dr. Hosein Forutan from Imam Khomeini hospital, Tehran University of Medical Sciences, who reviewed the manuscript. We also thank Amir Mirbagheri, Tehran University of Medical Sciences, for his special helps and supports.

## References

- BAGHBIAN M., SHABAZKHANI B., GHOFRANI H., FORUTAN H., DARIANI N., FARAHVASH M. *et al.* Efficacy of endoscopic ultrasound guided fine needle aspiration in patients with solid pancreatic neoplasms. *Saudi J. Gastroenterol.*, 2012, **18** : 358-63.
- GRESS F., GOTTLIEB K., SHERMAN S. *et al.* Endoscopic ultrasonography-guided fine-needle aspiration biopsy of suspected pancreatic cancer. *Ann Intern. Med.*, 2001, **134** : 459-64.
- HAREWOOD G.C., WIERSEMA M.J. Endosonography-guided fine needle aspiration biopsy in the evaluation of pancreatic masses. *Am. J. Gastroenterol.*, 2002, **97** : 1386-1391.
- Ductal adenocarcinoma.* In: HRUBAN R.H., PITMAN M.B., KLIMSTRA D.S. (ed). AFIP Atlas of Tumor Pathology. Tumors of the Pancreas, Washington, D.C. : American Registry of Pathology, 2007 : 111-64.
- WEBB T.H., LILLEMÖE K.D., PITT H.A. *et al.* Pancreatic lymphoma. Is surgery mandatory for diagnosis or treatment? *Ann. Surg.*, 1989, **209** : 25-30.
- SHIN H.J., LAHOTI S., SNEIGE N. Endoscopic ultrasound-guided fine needle aspiration in 179 cases : the M.D. Anderson Cancer Center experience. *Cancer*, 2002, **96** : 174-8.
- IMAOKA H., YAMAO K., BHATIA V., SHIMIZU Y., YATABE Y., KOSHIKAWA T. *et al.* Rare pancreatic neoplasms : the utility of endoscopic ultrasound guided fine-needle aspiration – a large single center study. *J. Gastroenterol.*, 2009, **44** : 146-153.
- FALCONI M., PLOCKINGER U., KWEKKEBOOM D.J. *et al.* Well-differentiated pancreatic nonfunctioning tumors/carcinoma. *Neuroendocrinology*, 2006, **84** : 196-211.

9. YAO J.C., EISNER M.P., LEARY C. *et al.* Population-based study of islet cell carcinoma. *Ann. Surg. Oncol.*, 2007, **14** : 3492-500.
10. JENSEN R.T. Natural history of digestive endocrine tumors. In: MIGNON M., COLOMBEL J.F. (ed). Recent advances in pathophysiology and management of inflammatory bowel diseases and digestive endocrine tumors, Paris : John Libbey Eurotext, 1999 : 192.
11. FRITSCHER-RAVENS A., BRAND L., KNOFEL W.T., BOBROWSKI C., TOPALIDIS T., THONKE F. *et al.* Comparison of endoscopic ultrasound-guided fine needle aspiration for focal pancreatic lesions in patients with normal parenchyma and chronic pancreatitis. *Am. J. Gastroenterol.*, 2002, **97** : 2768-75.
12. VOSS M., HAMMEL P., MOLAS G., PALAZZO L., DANCOUR A., O'TOOLE D. *et al.* Value of endoscopic ultrasound guided fine needle aspiration biopsy in the diagnosis of solid pancreatic masses. *Gut*, 2000, **46** : 244-9.
13. GINES A., VAZQUEZ-SEQUEIROS E., SORIA M.T., CLAIN J.E., WIERSEMA M. Usefulness of EUS-guided fine needle aspiration (EUS-FNA) in the diagnosis of functioning neuroendocrine tumors. *Gastrointest. Endosc.*, 2002, **56** : 291-6.
14. ARDENGH J.C., LOPES C.V., DE LIMA L.F., DE OLIVEIRA J.R., VENCO F., SANTO G.C. *et al.* Diagnosis of pancreatic tumors by endoscopic ultrasound-guided fine-needle aspiration. *World J. Gastroenterol.*, 2007, **13** : 3112-6.
15. WILSON J.L., KALADE A., PRASAD S., CADE R., THOMSON B., BANTING S. *et al.* Diagnosis of solid pancreatic masses by endoscopic ultrasound guided fine needle aspiration. *Intern. Med. J.*, 2009, **39** : 32-7.
16. MESA H., STELOW E.B., STANLEY M.W., MALLERY S., LAI R., BARDALES R.H. Diagnosis of nonprimary pancreatic neoplasms by endoscopic ultrasound guided fine needle aspiration. *Diagn. Cytopathol.*, 2004, **31** : 313-8.
17. DEWITT J.M., CHAPPO J., SHERMAN S. Endoscopic ultrasound-guided fine-needle aspiration of melanoma metastatic to the pancreas : report of two cases and review. *Endoscopy*, 2003, **35** : 219-22.
18. ELOUBEIDI M.A., JHALA D., CHHIENG D.C., JHALA N., ELTOUM I., WILCOX C.M. Multiple late asymptomatic pancreatic metastases from renal cell carcinoma : diagnosis by endoscopic ultrasound-guided fine needle aspiration biopsy with immunocytochemical correlation. *Dig. Dis. Sci.*, 2002, **47** : 1839-42.
19. DEWITT J., JOWELL P., LEBLANC J., MCHENRY L., MCGREEVY K., CRAMER H. *et al.* EUS-guided FNA of pancreatic metastases : a multicenter experience. *Gastrointest. Endosc.*, 2005, **61** : 689-96.
20. BECHADE D., PALAZZO L., FABRE M., ALGAYRES J.P. EUS-guided FNA of pancreatic metastasis from renal cell carcinoma. *Gastrointest. Endosc.*, 2003, **58** : 784-8.
21. FRITSCHER-RAVENS A., SRIRAM P.V., KRAUSE C., ATAY Z., JAECKLE S., THONKE F. *et al.* Detection of pancreatic metastasis by EUS-guided fine-needle aspiration. *Gastrointest. Endosc.*, 2001, **53** : 65-70.
22. ABBAS M.A., COLLINS J.M., MULLIGAN D.C. Renal cell carcinoma metastatic to the pancreas. *Am. J. Surg.*, 2001, **182** : 183-4.
23. SOHN T.A., YEO C.J., CAMERON J.L., NAKKEEB A., LILLEMOR K.D. Renal cell carcinoma metastatic to the pancreas : results of surgical management. *J. Gastrointest. Surg.*, 2001, **5** : 346-51.
24. PAPAVERAMIDIS T., PAPAVERAMIDIS S. Solid pseudopapillary tumors of the pancreas : review of 718 patients reported in English literature. *J. Am. Coll. Surg.*, 2005, **200** : 965-972.
25. KY A., SHILYANSKY J., GERSTLE J. *et al.* Experience with papillary and solid epithelial neoplasms of the pancreas in children. *J. Pediatr. Surg.*, 1998, **33** : 42-44.
26. BARDALES R., CENTENO B., MALLERY S. *et al.* Endoscopic ultrasound-guided fine-needle aspiration cytology diagnosis of solid pseudopapillary tumor of the pancreas : a rare neoplasm of elusive origin but characteristic cytomorphologic features. *Am. J. Clin. Path.*, 2004, **121** : 654-662.
27. JANI N., DEWITT J., ELOUBEIDI M., VARADARAJULU S., APPALANANI V., HOFFMAN B., BRUGGE W., LEE K., KHALID A., MCGRATH K. EUS-FNA for diagnosis of solid pseudopapillary tumors of the pancreas : a multicenter experience. *Endoscopy*, 2008, **40** : 200-203.
28. PELOSI G., IANNUCCI A., ZAMBONI G., BRESAOLA E., IACONO C., SERIO G. Solid and cystic papillary neoplasm of the pancreas : a clinicocytologic and immunocytochemical study of five new cases diagnosed by fine-needle aspiration cytology and a review of the literature. *Diagn. Cytopathol.*, 1995, **13** : 233-46.
29. JENG L.B., CHEN M.F., TANG R.P. Solid and papillary neoplasm of the pancreas. Emphasis on surgical management. *Arch. Surg.*, 1993, **128** : 433-6.
30. MARTIN R.C., KLIMSTRA D.S., BRENNAN M.F., CONLON K.C. Solid pseudopapillary tumor of the pancreas : a surgical enigma ? *Ann. Surg. Oncol.*, 2002, **9** : 35-40.
31. KONIARIS L.G., LILLEMOR K.D., YEO C.J. *et al.* Is there a role for surgical resection in the treatment of early-stage pancreatic lymphoma ? *J. Am. Coll. Surg.*, 2000, **190** : 319-30.
32. SAIF M.W. Primary pancreatic lymphomas. *JOP*, 2006, **7** : 262-73.