

An infrequent variant of Stauffer's syndrome

I. Woldie¹, P. Manickam², M. Choi¹, D. Shi³, F. Burks⁴, U. Vaishampayan¹

(1) Barbara Ann Cancer Institute, Wayne State University, Detroit Medical Center (DMC), Detroit MI ; (2) Wayne State University, DMC ; (3) Department of Pathology DMC, Detroit MI ; (4) Department of Urology, DMC.

To the Editor,

Cholestasis could be a paraneoplastic manifestation of underlying malignancies. Stauffer's syndrome is a rare paraneoplastic manifestation of renal cell carcinoma characterized by abnormal liver enzymes and usually without hepatic metastasis and jaundice. Little is known about the cholestatic variant of Stauffer's syndrome. Stauffer's syndrome variant is reported as one of the unusual presentations.

A 27 year old man was admitted to the hospital for generalized pruritis, yellowish discoloration of his eyes, and dark urine for 2 weeks. He also had nausea and few episodes of vomiting for 2 days.

On exam patient was deeply icteric, had upper abdominal tenderness with guarding and left flank mass. Laboratory work up revealed microcytic anemia, elevated AST, ALT and alkaline phosphatase with a primarily conjugated hyperbilirubinemia. Hepatitis profile showed negative hepatitis C Antibody, negative hepatitis A antibody and immunity to hepatitis B. Antinuclear antibody was negative and anti-smooth muscle antibody was elevated at 42.1 (Table 1).

Imaging with right upper quadrant ultrasound showed normal sized liver with homogeneous echotexture. There were no focal hepatic lesions and intrahepatic and extra hepatic biliary ducts were not dilated. Contrast enhanced CT of the abdomen revealed a 16cm mass arising from the lateral cortex of the left kidney and extending inferiorly thorough the retroperitoneum into the left iliac fossa. It has well defined sharp margins with no evidence of invasion of the surrounding structures. The mass was also highly vascular and drains into numerous collateral vessels on the left side of the abdomen. No abnormality was seen in the liver and pancreas. The spleen was moderately enlarged at 15 × 12 cms (Fig. 1). MRCP was normal with no intrahepatic or extrahepatic biliary ductal dilatation as was ERCP.

Patient then had left radical nephrectomy which was complicated by post operative bleeding requiring re-exploration. Pathology was consistent with renal cell carcinoma with negative resection margins (Fig. 2).

Subsequent laboratory data showed initial fall followed by persistent increase in conjugated bilirubin and alkaline phosphatase levels with a sharp drop after around day 20 post nephrectomy. Ultrasound guided liver biopsy done during periods of increasing bilirubin

Table 1. — Laboratory values at presentation and after nephrectomy

	Normal range	Presentation	Post nephrectomy*
Hemoglobin (gm/dl)	13.3-17.1	10.8	3.2
Hematocrit (%)	38.9-49.7	31.1	10
WBC (K/cumm)	3.5-10.6	5	21
Platelets (K/cumm)	150-450	261	437
AST (Units/L)	≤ 37	349	71
ALT (Units/L)	≤ 65	290	65
Alkaline phosphatase (Units/L)	50-136	1306	122
Bilirubin (total)	≤ 1.5	18.5	11.2
Bilirubin (Direct)	≤ 0.4	14.6	8.3
Albumin (gm/dl)	3.5-5.2	2.6	0.7
aPTT (sec)	23.2-34.1	34.8	63
Prothrombin time (sec)	9.6-11.8	13.6	21.7
ESR (mm/hr)	≤ 13	130	NA**
α-2 Macroglobulin (mg/dl)	131-293	262	NA**

* Day 23 after nephrectomy (last available laboratory value).

** Not available.

AST : aspartate aminotransaminase, ALT : alanine aminotransaminase, aPTT : activated partial thromboplastin time, ESR : erythrocyte sedimentation rate.

showed evidence of intrahepatic cholestasis with foci of hepatocyte injury.

The incidence of renal cell carcinoma is increasing in the United States partly due to increased use of imaging modalities (1). It classically presents hematuria, flank pain and flank mass. However, this classical presentation is seen in only few proportions of patients. Of interest are the various paraneoplastic manifestations that either precede or appear concomitantly with the diagnosis of renal

Correspondence to : Palaniappan Manickam, M.D., M.P.H., Department of Internal Medicine, Wayne State University, Detroit MI, 4100 John R, Detroit MI 48201. E-mail : pal.manickam@gmail.com

Submission date : 17/03/2012

Acceptance date : 30/03/2012

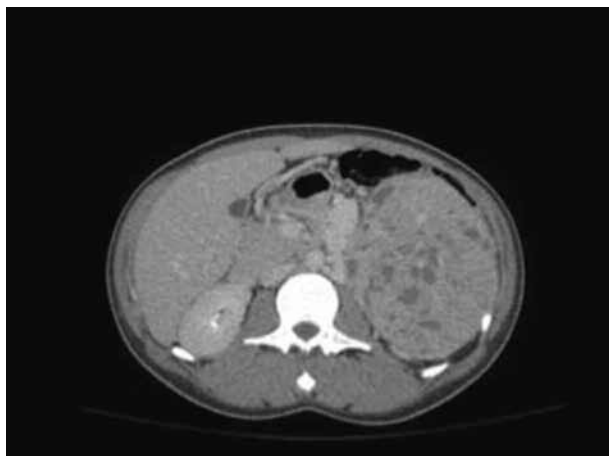

Fig. 1. — Contrast CT of the abdomen showing huge vascular mass arising from the left kidney (arrow).

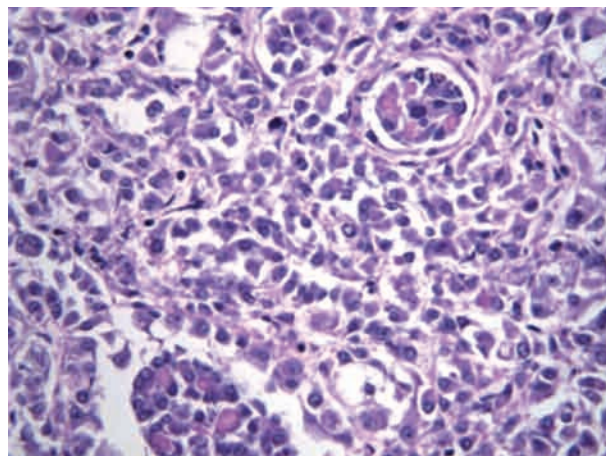


Fig. 2. — Renal biopsy showing malignant epithelial cells consistent with renal cell carcinoma.

cell carcinoma. These include but are not limited to thrombocytosis, hypercalcemia, and leukocytosis (2).

Liver involvement in malignancy could be due to direct metastatic spread, mass effect with compression of vital structures particularly the portal triad and paraneoplastic. Cholestasis mainly with elevated alkaline phosphatase is seen in renal cell carcinoma, bronchogenic carcinoma and adenocarcinoma of the prostate. Stauffer's syndrome, also called non-metastatic nephrogenic hepatic dysfunction syndrome is an interesting paraneoplastic manifestation of renal cell carcinoma that typically presents with cholestasis without jaundice. It is characterized by elevated alkaline phosphatase and α -2 globulin, increased ESR, thrombocytosis, prolonged prothrombin time and hepatosplenomegaly. Although not fully understood, the mechanism of Stauffer's syndrome is thought to be cytokine related particularly over expression of Interleukin-6 by tumor cells (3).

An unusual variant of Stauffer's syndrome with icteric cholestasis has also been described in literature. In all of the case reports of either classic or variant Stauffer's syndrome, the hepatic biochemical abnormalities normalized following nephrectomy (4).

The patient described above presented with symptoms and biochemical evidence of obstructive jaundice. There was no evidence of tumor or extrinsic compression in the hepatobiliary system per imaging. The finding of left renal mass that is consistent with renal cell carcinoma fits the presentation of variant Stauffer's syndrome. In addition, liver biopsy showed picture consistent with cholestasis, which is compatible with Stauffer's syndrome.

The patient had worsening of hepatic biochemical abnormalities after brief initial improvement following nephrectomy that is not typical of what was reported in literatures. Possible explanation could be patient's clinical deterioration from postoperative bleeding. Yet another possibility could be release of cytokines from the large tumor during surgical manipulation resulting in temporary worsening of the condition. Although the bilirubin level could not be followed until complete recovery (last laboratory data available on day 23 post nephrectomy), the precipitous fall in its level after around day 20 with normalization of alkaline phosphatase is indicative of complete biochemical recovery described in literature following nephrectomy (3,4).

Paraneoplastic manifestation from renal cell carcinoma could manifest in several forms and early suspicion and appropriate work up can lead to the appropriate diagnosis. Variant Stauffer's syndrome is a rare but a real presentation characterized with icteric cholestasis without liver metastasis in patients with renal cell carcinoma.

References

1. PANTUCK A.J. *et al.* Pathobiology, Prognosis, and Targeted Therapy for Renal Cell Carcinoma : Exploiting the Hypoxia-Induced Pathway : *Clinical Cancer Research*, Vol. 9, 4641-4652, October 15, 2003.
2. SKINNER D.G. *et al.* Diagnosis and management of renal cell carcinoma. A clinical and pathologic study of 309 cases. *Cancer*, 1971 Nov, **28** (5) : 1165-77.
3. MORLA D. *et al.* Stauffer's Syndrome Variant with Cholestatic Jaundice. *J. Gen. Intern. Med.*, 2006, **21** : C11-C13.
4. TOMADONI A. *et al.* Stauffer's syndrome with Jaundice, a Paraneoplastic manifestation of Renal cell Carcinoma : A case report. *Arch. Exp. Urol.*, 2010, **63** (2) : 154-156.