

## Mesalazine interstitial nephritis presenting as colitis ulcerosa exacerbation

S. Van Biervliet<sup>1</sup>, A. Raes<sup>2</sup>, J. Vande Walle<sup>2</sup>, M. Van Winckel<sup>1</sup>, E. Robberecht<sup>1</sup>, M. Praet<sup>3</sup>

Departments of (1) Paediatric Gastroenterology ; (2) Nephrology and (3) Pathology, Ghent University Hospital, Ghent, Belgium.

### Abstract

Mesalazine is the first line treatment in paediatric inflammatory bowel disease (IBD). There are several reports in the literature about nephrotoxicity (1/150 treated patients), from renal insufficiency to reversible nephritis. It is currently advised to follow creatinin in patients treated with mesalazine during the first 5 years of treatment ; however this may reveal the problem too late. As demonstrated in this paediatric case, a high degree of clinical suspicion is needed to diagnose the side effects before irreversible kidney damage occurs. Since the treatment of IBD exacerbation and mesalazine induced interstitial nephritis is based upon steroids, delayed diagnosis of the latter is at risk. (*Acta gastroenterol. belg.*, 2006, 69, 321-322).

**Key words** : mesalazine, inflammatory bowel disease, interstitial nephritis.

### Introduction

Mesalazine is frequently used in the treatment of inflammatory bowel disease (IBD). Mesalazine is the first line treatment in paediatric inflammatory bowel disease (IBD). There are several reports in literature about nephrotoxicity (1/150 treated patients) (1), from renal insufficiency to reversible nephritis (2,3). Although a recent epidemiological study concludes that the risk of renal disease in IBD is partly attributable to the underlying disease, mesalazine is recognised to cause interstitial nephritis (4). There is no relation with the dose or type of mesalazine used. Currently it is advised to use serum creatinin, to monitor for this complication (5). However, if we want to detect the renal problem before the stage of renal insufficiency, perhaps  $\alpha_1$ -microglobulinuria may be more sensitive.

Although in adult literature more than 30 cases have been described (2,3,6-13) this 11-year old girl is only the third paediatric case below the age of 16 in literature (14). However with the increasing occurrence of IBD in children (15) we should be vigilant for medication side effects.

### Case report

An 11-year-old girl diagnosed with left sided ulcerative colitis was treated with mesalazine (500 mg every 8 hours), after induction of remission using a short course of oral steroids. Three years following the diagnosis she was admitted with nausea, vomiting, abdominal pain, weight loss (-6 kg), asthenia and low grade fever (38,2°). There were loose stools without blood,

3 times a day. She complained of fatigue during the previous months. Laboratory tests showed an increased inflammation (sedimentation rate 35 mm/h, CRP 9 mg/dl) with ferriprive anaemia. Urea (0.17 g/L (normal limit 0.13-0.43 g/L)) and creatinin (0.88 mg/dL (normal limits 0.5-0.95 mg/dL)) were within the normal range. A colonoscopy showed no macroscopic abnormalities. The tests also showed leucocyturia (763 / $\mu$ L), proteinuria 0.6 g/L and an  $\alpha_1$ -microglobulin of 46.4 mg/L. Ultrasound examination showed hypodense kidneys with a decreased corticomedullary differentiation. Computed tomography revealed wedge formed hypodensities in both kidneys, interpreted as pyelonephritis (Fig. 1). The girl was treated with intravenous broad-spectrum antibiotics without any clinical effect. Urine and blood cultures remained negative.

Since neither the clinical picture nor the laboratory results improved, a kidney biopsy was performed. There was chronic active interstitial nephritis with a marking number of eosinophils in the infiltrate and focal glomerulosclerosis (Fig. 2). Immunofluorescent staining was negative. The immunoglobulin and complement concentrations were normal.

Mesalazine treatment was stopped and prednisolone (2 mg/kg/d) was started. All symptoms disappeared within 3 days. Inflammatory parameters disappeared and  $\alpha_1$ -microglobulin in the urine normalised within 2 weeks after the change in treatment. Based upon the level of  $\alpha_1$ -microglobulin in the urine, steroids were tempered and stopped. Four years after this adverse event, she had no treatment for her colitis ulcerosa and her renal function had normalised without persisting proteinuria (Serum : urea 0.22 g/L, creatinin 0.8 mg/dL ; Urine : protein 0 g/L  $\alpha_1$ -microglobulin < 2 mg/L).

### Discussion

Since the frequency of IBD is increasing during childhood (15,16), drug side effects will equally follow. At present Mesalazine treatment is the backbone of IBD treatment in paediatric patients. During the last 10 years

Correspondence address : S. Van Biervliet, Paediatric Gastroenterology, Ghent University Hospital, De Pintelaan 185, 9000 Ghent, Belgium. E-mail : stephanie.vanbiervliet@ugent.ac.be.

Submission date : 24.10.2005.  
Acceptance date : 24.04.2006.

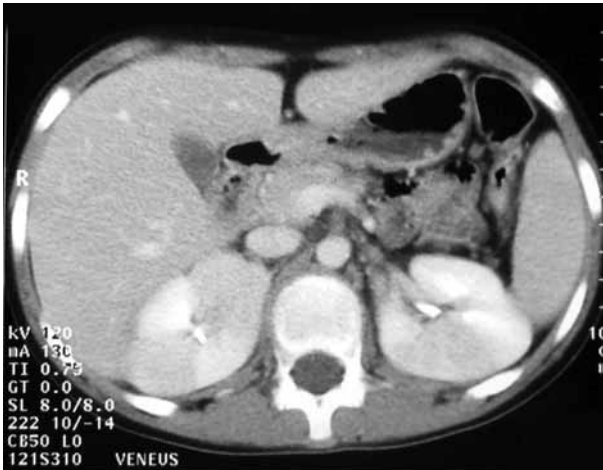

Fig. 1. — CT-scan demonstrating wedge formed lesions in both kidneys.

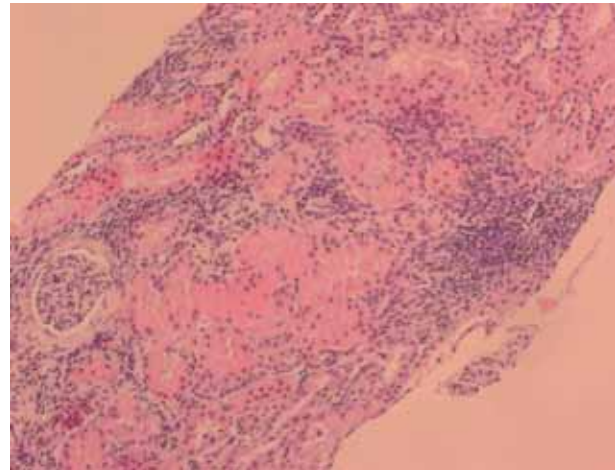


Fig. 2. — Light microscopic findings on renal biopsy. Chronic active interstitial nephritis with a marked number of eosinophils in the infiltrate and focal glomerulosclerosis.

several reports have linked mesalazine therapy to acute and chronic interstitial nephritis (2,3,6-14). However, pancreatitis, skin reactions, hepatitis and blood dyscrasias have also been reported (17). Most cases are diagnosed within the first 12 months of therapy (5). Yet some reactions appear as late as 5 years after the start of mesalazine (11). This patient was taking a slow release preparation of mesalazine for 3 years.

Symptoms of mesalazine nephrotoxicity are non-specific, sometimes mimicking a disease relapse (5). Early diagnosis is mandatory since 61% of the described cases have chronic renal failure and 13% develop end-stage renal disease (13). When diagnosis is made after 18 months of treatment, recovery of renal function is less frequent or only partial (2). Although proteinuria is only present in half of the described cases (13), it can perhaps draw our attention and lead to an early diagnosis. In this girl's case, after a two-week treatment with antibiotics (because of a supposed pyelonephritis), clinical symptoms disappeared within 3 days after stopping the responsible mesalazine. Treatment of the interstitial nephritis consisted of steroids, until disappearance of the proteinuria and normalisation of  $\alpha_1$ -microglobulin.

Steroids are easily used to treat relapses in IBD patients however a drug induced interstitial nephritis will also improve during this treatment. This explains why the diagnosis of mesalazine induced interstitial nephritis can be delayed in IBD patients (5) and a high vigilance is necessary.

## References

1. FOCKENS P., MULDER C.J.J., TYTGAT G.N.J., BLOK P., FERWERDA J. AND THE DUTCH PENTASA STUDY GROUP. Comparison of efficacy and safety of 1,5 vs 3,0 g oral slow-release mesalazine (pentasa) in the maintenance treatment of ulcerative colitis. *Eur. J. Gastroenterol. Hepatol.*, 1995, **7** : 1025-30.
2. WORLD M.J., STEVENS P.E., ASHTON M.A., RAINFORD D.J. Mesalazine-associated interstitial nephritis. *Nephrol. Dial. Transplant.*, 1996, **11** : 614-21.
3. FRANDBEN N.E., SAUGMANN S., MARCUSSEN N. Acute interstitial nephritis associated with the use of mesalazine in inflammatory bowel disease. *Nephron*, 2002, **92** : 200-2.
4. VAN STAA T.P., TRVIS S., LEUFKENS H.G.M., LOGAN R.F. 5-aminosalicylic acids and the risk of renal disease : a large British epidemiologic study. *Gastroenterology*, 2004, **126** : 1733-9.
5. CORRIGAN G., STEVENS P.E. Review article : interstitial nephritis associated with the use of mesalazine in inflammatory bowel disease. *Aliment Pharmacol. Ther.*, 2000, **14** : 1-6.
6. MEHTA R.P. Acute interstitial nephritis due to 5-aminosalicylic acid. *Can. Med. Assoc. J.*, 1990, **143** : 1031-2.
7. THULUVATH P.J., NINKOVIC M., CALAM J., ANDERSON M. Mesalazine induced interstitial nephritis. *Gut*, 1994, **35** : 1493-6.
8. WITTE T., OLBRIGHT C.J., KOCH K.M. Interstitial nephritis associated with 5-aminosalicylic acid. *Nephron*, 1994, 481-2.
9. MANENTI L., DEROSA A., BUZIO C. Mesalazine associated interstitial nephritis twice in the same patient. *Nephrol. Dial. Transplant.*, 1997, **12** : 2031.
10. HÄMLING J., RAEDLER A., HELMCHEN U., SCHREIBER S. 5-aminosalicylic acid-associated renal tubular acidosis with decreased renal function in Crohn's disease. *Digestion*, 1997, **58** : 304-7.
11. POPOOLA J., MULLER A.F., POLLOCK L., O'DONNELL P., CARMICHAEL P., STEVENS P. Late onset interstitial nephritis associated with mesalazine treatment. *BMJ*, 1998, **317** : 795-7.
12. HAAS M., SHETYE K.R. Acute renal failure in a 53-year-old Woman with crohn's disease treated with 5-Aminosalicylic acid. *Am. J. Kidney Dis.*, 2001, **1** : 205-9.
13. AREND L.J., SPRINGATE J.E. Interstitial nephritis from mesalazine : case report and literature review. *Pediatr. Nephrol.*, 2004, **19** : 550-3.
14. BENADOR N., GRIMM P., LEMIRE J., GRISWOLD W., BILLMAN G., REZNIK V. Interstitial nephritis in children with Crohn's disease. *Clinical Pediatrics*, 2000, **39** : 253-4.
15. SAWCZENKO A., SANDHU B.K., LOGAN R.F., JENKINS H., TAYLOR G., MIAN S., LYNN R. Prospective survey of childhood inflammatory bowel disease in the British Isles. *Lancet*, 2001, **7** : 1093-4.
16. WALKER-SMITH J., MURCH S. Crohn's disease and abdominal tuberculosis. In : WALKER-SMITH J., MURCH S. (eds). Diseases of the small intestine in childhood. Oxford : ISIS Medical media : fourth edition, 1999, 299-328.
17. RANSFORD R.A.J., LANGMAN M.J.S. Sulphalazine and mesalazine : serious adverse reactions re-evaluated on the basis of suspected adverse reaction reports to the Committee on Safety of Medicines. *Gut*, 2002, **51** : 536-39.